



Cardiac Monitoring (rev)

Barbara Drew, RN, PhD
University of California
San Francisco



PHILIPS

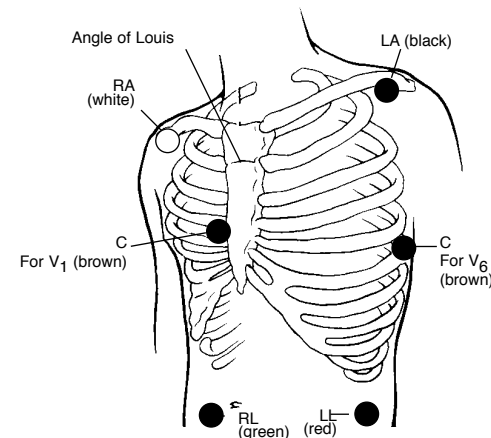
AMERICAN ASSOCIATION
of CRITICAL-CARE
NURSES

A Supplement to *Critical Care Nurses*

Philips PN #5990-0487
Printed in USA
March 15, 2002

Normal ECG criteria	
Rate	Atrial and ventricular rates are the same. In adults, 60 to 100 cycles/min; in infants and children, within normal limits for age
Rhythm	Regular, with variance between P-P and R-R intervals less than 0.16 second
P wave	Present and 1:1 with the QRS
Shape	Uniformly rounded without peaking or notches
Size	Amplitude <3.0 mm, width 1.5 - 2.5 mm or duration of 0.06 - 0.11 second
Axis	0 to +90 degrees
Deflection	Upright in leads I, II, aVF, V ₄ through V ₆ ; inverted in aVR; may be flat, inverted, or biphasic in leads III, V ₁ , and V ₂
PR interval	Consistent; in adults, 0.12 - 0.20 second; in infants and children, 0.11 - 0.18 second
QRS	Follows the P wave; QRS interval is 0.04 - 0.10 second
Q wave	Duration is <0.03 second; depth is 1-2 mm in leads I, aVL, V ₅ , and V ₆ ; deep QR or QS in aVR and possibly in lead III
Amplitude	5-25 mm in limb leads, 5-30 mm in V ₁ and V ₆ , 7-30 mm in V ₂ and V ₅ , 9-30 mm in V ₃ and V ₄
Axis	-30 to +100 degrees
QT interval	Interval <50% preceding R-R; QTc <0.42 second (men) and <0.43 second (women)
ST segment	Follows isoelectric line, slight curve at proximal portion of the T wave Not depressed more than 1 mm May be normally elevated 1-2 mm in V ₁ through V ₃
T wave	Asymmetric and slightly rounded, without sharp points or large notches
Deflection	Should be in the same direction as QRS: upright in leads I, II, aVF, V ₄ through V ₆ ; inverted in aVR; varied in leads III, aVL, and V ₁ through V ₃

Standard electrode placement with a 5-lead set



Leads recommended for arrhythmia monitoring

For monitors with 5-leadwire patient cables

1st choice

Single-lead monitoring: V₁

Dual-lead monitoring: V₁ + II

2nd choice

Substitute V₆ for V₁ when the patient cannot have an electrode at the sternal border or when QRS amplitude is not adequate for optimized computerized arrhythmia monitoring.

Leads recommended for ischemia monitoring

Inferior myocardial infarction or RCA angioplasty/stent	II, III, or aVF
Anterior myocardial infarction or LAD angioplasty/stent	V ₂ or V ₃
Posterior or LCX angioplasty/stent	V ₂ or V ₃

Wide QRS tachycardias: distinguishing supraventricular tachycardia with bundle branch block or aberrant conduction from ventricular tachycardia (VT)

Four-step approach to diagnosis
Using the bedside monitor:

1. Presence of A-V dissociation → Yes = VT
2. QRS width > 0.16 second → Yes = VT
3. Electrical axis -90° - ±180° → Yes = VT
4. QRS morphology in leads V₁ or V₆ → Yes = VT

(MCL₁ or MCL₆) suggestive of VT (see table right)

Axis determination using lead I and aVF

QRS polarity lead I	QRS polarity lead aVF	Axis
		Normal (0° to +90°)
		Right (+90° to ±180°)
		Left (0° to -90°)
		Highly abnormal (-90° to ±180°)

Electrode placement with a 3-lead set

Standard lead placement: RA (white), LA (black), LL (red)

For MCL₁ select lead I
For MCL₆ select lead II

Leads recommended for monitors with 3-lead patient cables:
1st choice, MCL₁; 2nd choice, MCL₆; 3rd choice, lead II

V ₁ or MCL ₁	V ₆ or MCL ₆
Ventricular tachycardia	
Monophasic R	Biphasic rS with R:S ratio <1.0
Taller left peak	Monophasic Q
Biphasic RS	Notched QS
Biphasic qR	Biphasic qR
Any of the following in V ₁ or V ₂ : a) R >30 ms b) Slurred or notched S descent c) QRS onset to S nadir >60 ms	Intrinsicoid deflection ≥ 70 ms

Supraventricular tachycardia with bundle branch block or aberration

Bimodal rR' or triphasic rsR'	Triphasic qRs with R:S ratio >1.0
All of the following in V ₁ and V ₂ : a) R ≤ 30 ms or no R b) Straight S descent c) QRS onset to S nadir ≤ 60 ms And , no Q in V ₆	Intrinsicoid deflection ≤ 50 ms

Unhelpful QRS morphologies

Slurred or notched taller right peak	Monophasic R
	Taller left or right peak
	Biphasic Rs with R:S ratio >1.0

*Applies only to tachycardias with a positive waveform in V₁.

ECG indicators of myocardial damage

Ischemia Inverted T wave ST depression	<ul style="list-style-type: none"> • Inverted T waves in leads with upright QRS deflections. • Deeply inverted T waves in precordial leads. • Transient ST-segment depression reflects acute ischemia. • Permanent ST-segment depression may indicate digitalis effect, LVH.
Injury Elevated ST segment	<ul style="list-style-type: none"> • Sign of an acute process; returns to baseline with time. • ST elevation may indicate pericarditis. • Determine location of injury similar to MI location process. • ST depression that occurs in an ECG and that also has ST elevation in other leads reflects reciprocal changes.
Infarction Q wave changes	<ul style="list-style-type: none"> • Evaluate Q wave size—normally small in leads V₅ and V₆; normally deep in leads III and aVR • Prolonged Q wave is ≥ 0.04 second. • Loss of R wave V₁ through V₃

12-lead placement

Mason-Likar (modified)	EASI™

References

1. Drew BJ. Bedside electrocardiographic monitoring: state of the art for the 1990s. *Heart Lung*. 1991;20:610-623.
2. Drew BJ. Bedside electrocardiogram monitoring. *AACN Clin Issues*. 1993;4:25-33.
3. Drew BJ, Krucoff MW, for the ST-Segment Monitoring Practice Guideline International Working Group. Multilead ST-segment monitoring in patients with acute coronary syndromes: a consensus statement for healthcare professionals. *Am J Crit Care*. 1999;2:372-388.